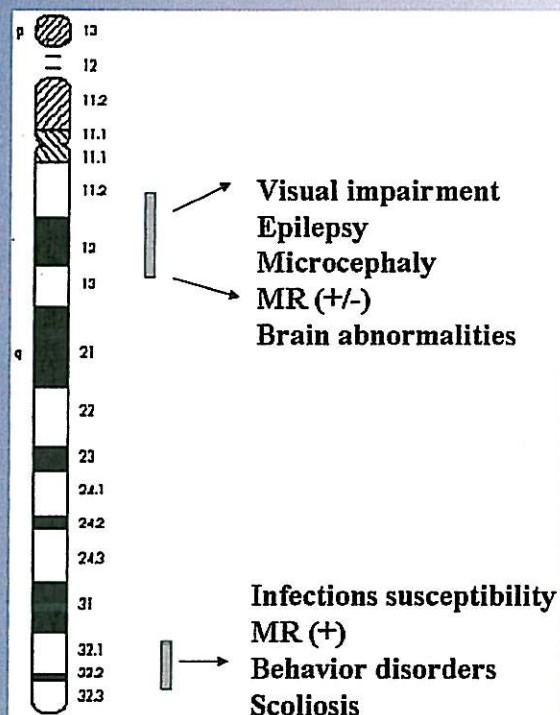


# AMERICAN JOURNAL OF medical genetics

PART  
A

VOLUME 149A NUMBER 6 JUNE 2009



FOUNDED BY JOHN M. OPITZ, MD

# The Ring 14 Syndrome: Clinical and Molecular Definition

Marcella Zollino,<sup>1</sup> Laura Seminara,<sup>1</sup> Daniela Orteschi,<sup>1</sup> Giuseppe Gobbi,<sup>2</sup> Simona Giovannini,<sup>2</sup> Elvio Della Giustina,<sup>3</sup> Daniele Frattini,<sup>3</sup> Angela Scarano,<sup>3</sup> and Giovanni Neri<sup>1\*</sup>

<sup>1</sup>Istituto di Genetica Medica, Università Cattolica del S. Cuore, Roma, Italy

<sup>2</sup>Neuropsichiatria Infantile, Ospedale Maggiore, Bologna, Italy

<sup>3</sup>Neuropsichiatria Infantile, Arcispedale S. Maria Nuova, Reggio Emilia, Italy

Received 16 September 2008; Accepted 4 March 2009

The ring 14 (r14) syndrome is a rare condition, whose precise clinical and genetic characterization is still lacking. We analyzed a total of 20 patients with r14 and another 9 patients with a linear 14q deletion. The ring was complete, with no apparent loss of chromosome material, in 6 cases; a terminal 14q deletion, varying in size from 0.65 to 5 Mb, was detected in the remaining 14 cases. Deleted ring chromosomes were 70% paternal and 30% maternal. UPD (14) was never detected. With respect to the linear 14q deletions, three were proximal, varying in size from 4 to 7.2 Mb, and six distal, varying in size from 4.8 to 20 Mb. The majority of the linear deletions were also of paternal origin, and UPD (14) was excluded in all cases. Clinically, the r14 syndrome was characterized by a recognizable phenotype, consisting of shortness of stature, a distinctive facial appearance, microcephaly, scoliosis, and ocular abnormalities, which included abnormal retinal pigmentation, strabismus, glaucoma, and abnormal macula. All patients except one had mental retardation. Drug-resistant epilepsy was another highly consistent finding. Aggressive and hyperactive behavior was noted in about half of the patients. Based on genotype–phenotype correlations, we could deduce that retinal abnormalities, epilepsy, microcephaly, and mental retardation map within the proximal 14q11.2–q12 region. Likewise, behavior disorders and scoliosis could be assigned to the 14q32 region. © 2009 Wiley-Liss, Inc.

**Key words:** ring chromosome 14; chromosome 14 deletions; epilepsy

## INTRODUCTION

The ring 14 (r14) syndrome is a rare cytogenetic disorder, reported so far in about 50 patients [for a review see van Karnebeek et al., 2002]. A common phenotype is described, consisting of microcephaly, a distinctive facial appearance, ocular abnormalities, in particular retinal dystrophy, developmental delay, and drug-resistant epilepsy. However, precise clinical and genetic characterization of this condition is still lacking. Two recent contributions [van Karnebeek et al., 2002; Schlade-Bartusiak et al., 2005] provide a good database and address the problematic issue of comparing the

### How to Cite this Article:

Zollino M, Seminara L, Orteschi D, Gobbi G, Giovannini S, Giustina ED, Frattini D, Scarano A, Neri G. 2009. The ring 14 syndrome: Clinical and molecular definition. *Am J Med Genet Part A* 149A:1116–1124.

phenotypic effects caused by 14q deletions occurring within a ring chromosome, with those caused by linear deletions of similar size and position. Particularly intriguing is the presence of two manifestations: seizures and retinal pigmentary abnormalities. The former is always present, the latter very frequent in the r14 syndrome. Neither has been reported in patients with comparable linear deletions affecting the terminal 14q24qter region.

In an attempt to construct a deletion map and to establish genotype–phenotype correlations, we analyzed both clinically and genetically a total of 20 new patients with the r14 syndrome, as well as 9 subjects with a linear 14q deletion encompassing proximal or distal chromosome 14 regions. The phenotype analysis reported in this article includes a detailed physical and neuropsychological evaluation. Genetic tests include standard chromosome analysis by R(RBG) banding of at least 100 metaphases from cultured lymphocytes of patients and parents; locus-specific FISH analysis with a total of 62 properly selected BAC probes; array-CGH at various levels of resolution; microsatellite segregation analysis, to establish the parental origin of the abnormal chromosome 14 and the possible occurrence of uniparental disomy (UPD).

Pathogenic mechanisms leading to the ring 14 syndrome are discussed.

Grant sponsor: Associazione Ring14, Reggio Emilia, Italy.

\*Correspondence to:

Giovanni Neri, Istituto di Genetica Medica, Università Cattolica, Largo F. Vito, 1, 00168 Roma, Italy. E-mail: gneri@rm.unicatt.it

Published online 13 May 2009 in Wiley InterScience

(www.interscience.wiley.com)

DOI 10.1002/ajmg.a.32831

## MATERIALS AND METHODS

### Patients

The majority of the reported patients were examined at dedicated clinics during meetings of the Ring 14 family support group. Consent forms approved by the local IRB were signed by parents or legal guardians, regarding both physical examination and performance of genetic tests. A total of 20 patients with ring chromosome 14 participated in the study. They were 11 males and 9 females, aged 1–36 years. Clinical analysis included phenotypic examination, neuropsychological evaluation, brain MRI, EEG studies, and fundoscopic examination. A formal IQ test could not be administered to several cases, due to the severity of the delay, especially language delay, and to the impairment of social skills. The evaluations were mainly qualitative, based on direct observation and semi-structured questionnaire. Whenever possible, Wechsler or Bayley scales were employed, and IQ values varied from mildly to severely delayed.

Another nine patients with linear 14q deletions affecting different chromosome regions were comparatively analyzed. They were four males and five females, aged 1–33 years.

Included in this study is also a 5-year-old female with a balanced  $t(10;14)(q25;q12)$  translocation, who showed phenotypic features consistent with the proximal 14q deletion syndrome.

### Genetic Tests

**Conventional cytogenetics.** Conventional chromosome analysis was performed by RBG banding on 100 cells from peripheral blood lymphocytes, with the purpose of verifying the stability and mosaic status of the ring. This analysis (100 metaphases) was extended to the parents.

**FISH analysis.** Conventional FISH analyses were performed on metaphase chromosomes in all patients, with a total of 62 molecular probes (RP11 library) encompassing cytogenetic breakpoints on

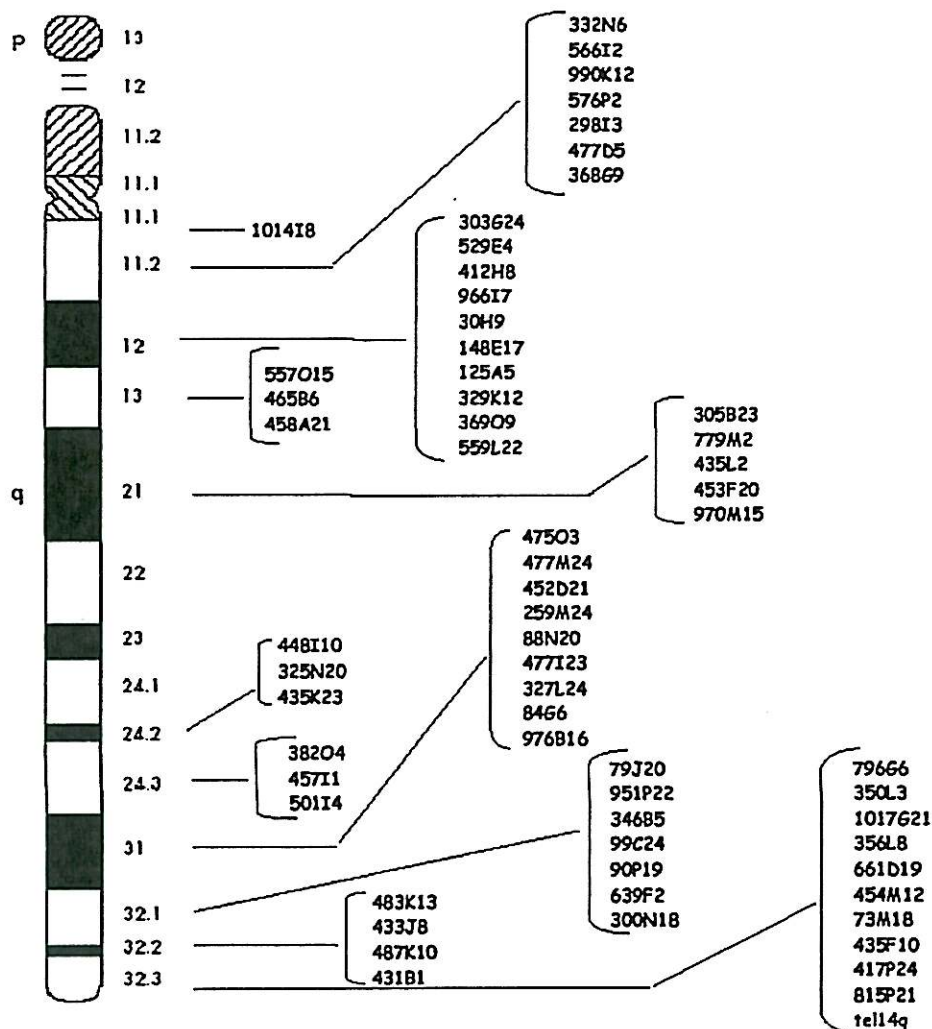


FIG. 1. Map of the molecular probes (RP11 library) tested by FISH, as established on ensembl database ([www.ensembl.org](http://www.ensembl.org)).

14q, at an average distance of 500–1,000 kb. In patients with a ring chromosome 14, the terminal 5 Mb region was more finely analyzed with probes mapping at an average distance of 200–500 kb. Molecular probes are listed within Figure 1. A subtelomeric probe tested in all patients by FISH lies at 70 kb from the end of 14q, according to the manufacturer (Vysis, Abbott Molecular, Chicago, IL).

**Array-CGH.** Array-CGH analysis was performed in 10 of the 20 patients with ring chromosome 14, in 1 patient with a linear 14q deletion, and in the patient with a balanced  $t(10;14)$  translocation. In eight patients, array-CGH was performed as described by Menten et al. [2006], using slides provided by VIB MicroArrays Facility ([www.microarrays.be](http://www.microarrays.be)) (University of Leuven, Leuven, Belgium), containing more than 3,500 BAC, PAC, and cosmid clones with an average resolution of 1 Mb. The most distal probe maps at about 150 kb from the 14q end. Results were analyzed using

the software available on the website <http://aulne8.esat.kuleuven.be:8080/loop/authenticate.jsp>.

Another four patients were analyzed using Agilent oligonucleotide-array kit 44B (Human Genome CGH Microarray Kit 44B; Agilent Technologies, Santa Clara, CA), with an average resolution of about 75 kb, following the manufacturer's instructions. The most distal probe in this array maps at about 40 kb from the 14q end.

High-resolution array-CGH (Agilent 244, average resolution 30 kb) was performed in patient 30, carrying an apparently balanced  $t(10;14)$  translocation.

**Microsatellite segregation analysis.** This analysis was carried out with the following markers: *D14S583*, *D14S63*, *D14S77*, *D14S1008*, *D14S267*, *D14S1007*, *D14S1419*, and *D14S1420* to establish the parental origin of the rearranged chromosome, as well as possible UPD (14).

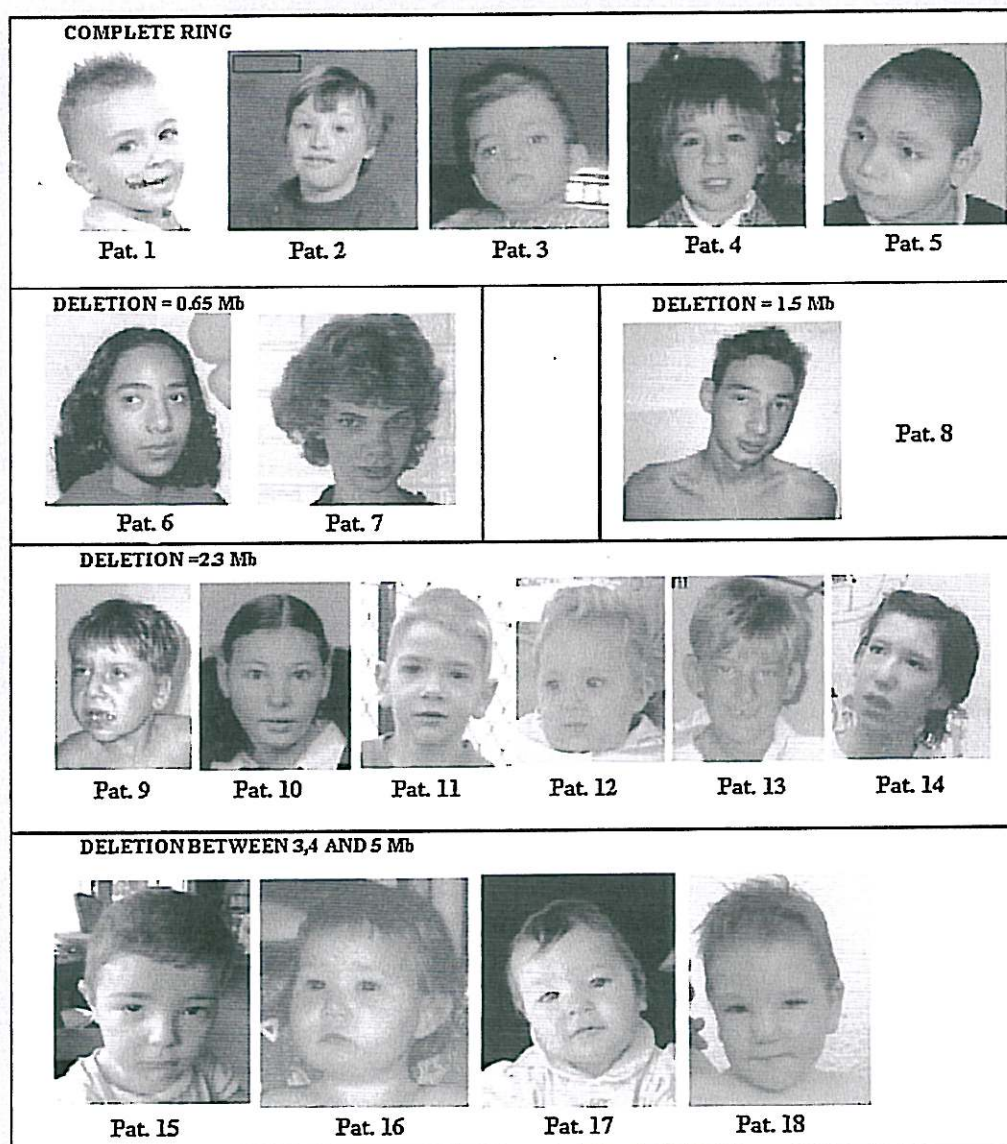


FIG. 2. Facial appearance of patients with r14, grouped on the basis of different (or absent) 14q deletions.

TABLE 1. Clinical-Genetic Data of Patients With Ring 14 (n = 20)

Patient no.	Sex	Age (years)	Cells with mon. 14 (N/100)	Del (Mb)	Deleted probes distal; proximal	Epilepsy	Hypotonia	Microcephaly	Language impairment	MR	Facies	Scoliosis	Infections susceptible	Ocular abnormalities	Behavior
1	F	17	20	0.65 <sup>a</sup>	Tel 14q; CTC-8ZDM16	+	+	+	+	+/+++	+	-	+	Strabismus myopia	Quiet
2	F	18	5	2 <sup>a</sup>	Tel 14q; A_14_P135856	+	+	+	+	+++	+	+	+	Abnormal macula	Autistic traits
3	M	3	15	<0.2 <sup>a</sup>	None; none	+	+	+	+	+++	-	-	+	Abnormal retinal pigmentation	Loving, social
4	F	13	23	2.5	Tel 14q; RP11.435F10	+	-	+	+	++	-	+	-	-	Episodes of self aggressiveness
5	M	4	19	2.5 <sup>a</sup>	Tel 14q; RP11.435F10	+	+	+	+	++	+	-	-	-	Social/ hypericinetic/ aggressive
6	M	10	17	<0.2	None; none	+	+	+	+	+++	-/+	+	+	-	Quiet
7	M	36	17	<0.2	None; none	+	+	+	+	+++	+/-	+	+	Bilateral glaucoma strabismus	Loving/ aggressive
8	F	23	15	0.65	Tel 14q; none	+	+	+	+	++	+	+	+	Retinitis pigmentosa	Social/ aggressive
9	F	2	21	4.3 <sup>a</sup>	Tel 14q; RP11.365N19	+	+	+	+	+	+	+	-	-	Social, quiet
10	M	1	21	<0.2 <sup>a</sup>	None; none	+	+	+	+	?	+	-	-	-	NA
11	M	3	19	3.4 <sup>a,b</sup>	Tel 14q; RP11.454M12	+	+	+	+	+++	+	-	+	Strabismus	Quiet
12	F	9	18	<0.2	None; none	+	-	+	-	+/-	+/-	-	-	Abnormal macula	Social, loving
13	M	5	20	2.5 <sup>a</sup>	Tel 14q; RP11.435F10	+	-	+	+	++	+	-	+	Abnormal retinal pigmentation	Social/ aggressive/ hypericinetic
14	M	16	20	1.5	Tel 14q; RP11.815P21	+	+	+	+	+++	+	+	-	-	Quiet
15	M	1	17	5	Tel 14q; RP11.796G6	+	+	+	+	+	+	-	+	-	Social, quiet
16	F	1	19	2.5	Tel 14q; RP11.435F10	+	+	+	+	?	+	-	+	-	Social, loving
17	M	14	19	2.5 <sup>a</sup>	Tel 14q; RP11.435F10	+	+	+	+	++	+	+	-	Abnormal retinal pigmentation	Social/ aggressive
18	F	5	17	3.8 <sup>a</sup>	Tel 14q; RP11.454M12	+	+	+	+	+++	+	-	-	-	Social/ aggressive/ hypericinetic
19	M	11	18	<0.2	None; none	+	+	+	+	++	+	-	-	Strabismus, abnormal retinal pigmentation	NA
20	F	2	10	0.65	Tel 14q; none	+	+	+	-	?	+	-	-	Abnormal retinal pigmentation	NA

NA, not available; -, not present.

<sup>a</sup>A-CGH also performed.<sup>b</sup>Partial 14q duplication of 2.5 Mb, contiguous to the deletion, also found.

## RESULTS

### Clinical Findings

Clinical findings common to both groups of patients described below can be summarized as follows. Prenatal history was in general non-contributory and measurements at birth were on average normal. Hands and feet were normal, with normal palmo-plantar creases and dermatoglyphics. Genitalia were normal in boys. They were not evaluated in girls, but there was no mention of any problems by the parents. Menarche occurred at 11 years in three of four adult females, at 13 years in one and menses were reported normal.

### Ring 14 Patients

At the time of our observation, most patients presented with distinctive facial characteristics, including long and sometimes slightly asymmetric face, full cheeks, high forehead, hypoplastic supraorbital ridges, straight eyebrows, deep set and downslanting eyes with short palpebral fissures, and apparent hypertelorism. The nose was short with a bulbous tip, the philtrum long and the mouth small with downturned corners. Ring 14 patients with deletions of various extents are depicted in Figure 2. Other consistent clinical signs were muscular hypotonia (14/20), microcephaly of postnatal onset (20/20), and ocular problems (13/20) that included retinal pigmentary anomalies in five patients, retinitis pigmentosa in one, cataract in one, strabismus, maculopathy, glaucoma and myopia in the remaining six patients. All the patients experienced drug-resistant epilepsy, usually with onset in the first months of life. Reported seizures were of various types, including generalized, partial, and mixed. Crises were tonic-adversive at onset, with a tendency to group in clusters towards a status epilepticus. Epileptic manifestations tended to decrease in late adolescence. The seizure disorder will be described in detail in a separate report. Mental delay was present in all patients except one and tended to be of severe degree in most cases. The language area was most severely affected. Other component manifestations were behavior disorders, typically hyperactivity with occasional bursts of aggressiveness, motoric stereotypies, such as hand flapping, and echolalia. Scoliosis and café-au-lait spots were noted in some patients. Major malformations were practically absent. One patient had mild right pulmonary artery obstruction.

Brain MRI was performed in 11 patients, and in 7 of them recurrent findings were detected, consisting of diffuse supratentorial hypoplasia, ventricular dilatation, corpus callosum anomalies (agenesis or hypoplasia), and hippocampal abnormalities. A summary of the clinical findings is provided in Table I.

All the patients exhibited the ring in an average 82% of the cells, the remaining 18% being monosomic for chromosome 14, with the only exception of patient 2, who exhibited the chromosome 14 monosomy in 5% of the cells (Table I). No deletions of chromosome material within the terminal 14q region was detected by FISH in six patients (30%). A small terminal deletion, varying in size from 0.5 to 5 Mb was detected in 14 patients (70%). In one of them (Patient 11) a cryptic 14q duplication encompassing the 2.5 Mb region proximal to the deleted segment was identified by

array-CGH. This was the only additional rearrangement found in those 10 patients who were also studied by array-CGH.

A biparental inheritance of chromosomes 14 was ascertained in all the families (total 16) that underwent this investigation.

Parental origin of the deleted ring 14 was ascertained in 10 patients. It was paternal in seven cases and maternal in three. Normal chromosomes were detected in all parents but one, the healthy father of patient 14, who had a ring chromosome 14 in 3 of 288 analyzed cells.

### Linear 14q Deletion Patients

Three patients were observed with a linear 14q deletion affecting the proximal 14q11q21 region (Fig. 3). They presented with acquired microcephaly, a round face, large eyes and bulbous nose, mental retardation, and visual impairment. Overall, clinical manifestations were less severe than those observed in the r14 patients (Table II). Patient 6 suffered from gastro-esophageal reflux and chronic constipation.

Another six patients carried a linear 14q deletion within the terminal 14q24q32.3 region. They presented with minimal facial dysmorphisms, mental retardation of variable degree and scoliosis (Table II). In addition, patient 22 had mild pulmonary stenosis, patient 24 had clubfoot, umbilical hernia and unilateral renal hypoplasia, and patient 26 had clubfoot.

The chromosomal rearrangements, ring as well as linear, are summarized in Figure 4.

### Genotype-Phenotype Correlations

Although the degree of mental delay was, on average, severe, there was a great range of variability, independent of the presence and extent of the deletion within the ring, but consistently correlated to the severity of the seizure disorder. Thus, it is likely that epilepsy and mental retardation are caused by the ring configuration, more than by loss of chromosomal material.

Typical facial characteristics occurred in association with deleted rings, being almost absent in cases with a "complete" ring, suggest-

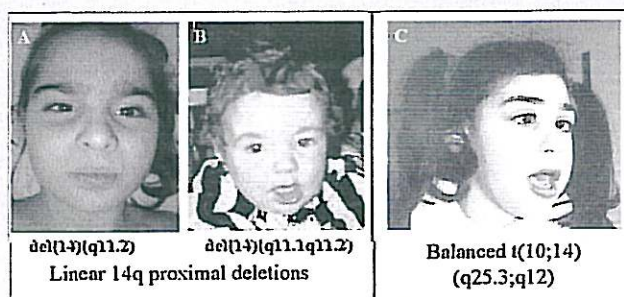

FIG. 3. Facial appearance of patients with a linear deletion affecting the proximal 14q region, and of the patient with a balanced  $t(10;14)(q25.3;q12)$  translocation. The similarity between the former and the latter is noteworthy.

TABLE II. Clinical-Genetic Data of Patients With Linear 14q Deletions (n = 9)

Patient No	Sex	Age (years)	Karyotype	Del (Mb)	Deleted probe; distal proximal	Epilepsy	Hypotonia	Microcephaly	Language impairment	MR	Dysmorphic facies	Scoliosis	Infections susceptible	Ocular abnormalities	Behavior
21	F	6	del(14)(q11.2q12)	7.2	RP11-36909; RP11-47705	+	+	+	+	+++	+	-	-	Strabismus, downgaze, cortical visual impairment	Social, introverted, loving
22	F	19	del(14)(q24.3q32.12)	15	RP11-639F2; RP11-50114	-	+	-	+	+++	+	+	+	-	Motor stereotypies, quiet during childhood, aggressive during adolescence
23	F	4	del(14)(q32.31qter)	4.8	Tel 14q; RP11-35618	NA	NA	NA	NA	NA	NA	NA	NA	NA	NA
24	F	33	del(14)(q32.3q32.2)	11	RP11-487K10; RP11-88N20	-	+	<sup>b</sup>	-	++	+	-	-	Strabismus	Aggressive, compulsive
25	M	18	del(14)(q24.3q32.13)	20	RP11-120E11; RP11-38204	-	+	+	+	+++	+	+	+	Strabismus, ptosis, severe myopia	Hyperactive, aggressive, hands flapping, echolalia
26	M	5	del(14)(q31.12q32.2)	8	RP11-431B1; RP11-90P19	+	+	<sup>b</sup>	+	++	+	-	-	NA	NA
27	F		del(14)(q31.2q32.2)	15 <sup>a</sup>	A_14_P135130; A_14_P13474	NA	NA	NA	NA	NA	NA	NA	NA	NA	NA
28	F	9	del(14)(q11q11.2)	4	RP11-567P2; RP11-332N6	-	+	-	+	+++	+	-	-	Retinal pigmentation abnormalities	Autistic traits, motor stereotypies
29	F	11	del(14)(q11.1q11.2)	6	RP11-303G24; RP11-332N6	NA	+	NA	+	++	+	-	+	NA	NA
30	F	6	t(10;14)(q25.3q12)	0 <sup>a</sup>		+	+	+	+	+++	+	NA	-	Strabismus	NA

Clinical signs in a patient with an apparently balanced t(10;14) translocation are also shown.

NA, not available; -, not present.

<sup>a</sup>Array-CGH also performed.<sup>b</sup>Macrocephaly.

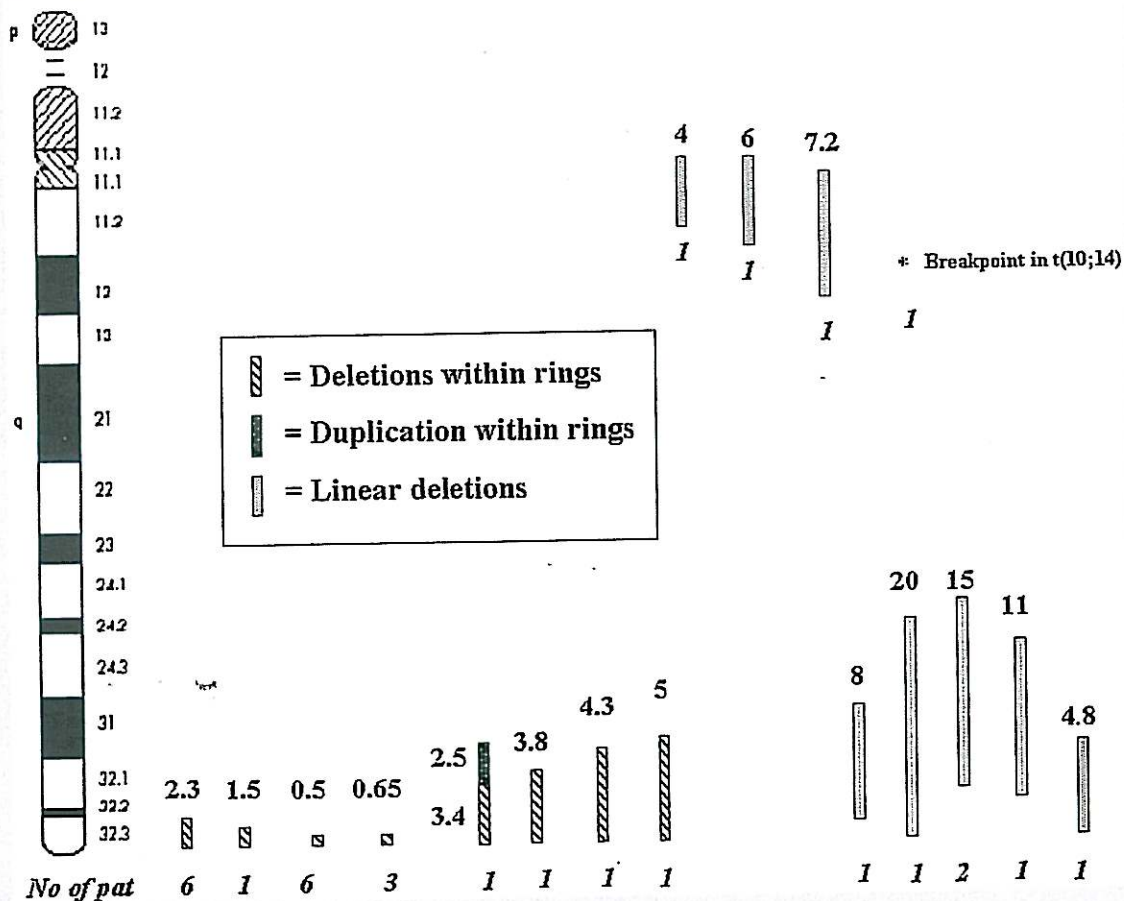


FIG. 4. Physical mapping and relative extent of all 14q rearrangements.

ing that genes for facial characteristics map on the terminal portion of chromosome 14q.

By comparing clinical signs of patients with a ring chromosome with those of patients carrying a proximal or distal 14q linear deletion, we concluded that seizures, ocular anomalies, and microcephaly are attributable to genes proximally located on 14q11q13 [Bisgaard et al., 2006]. Haploinsufficiency of these genes is structural in cases with a linear deletion. In cases with a ring, we assume a silencing position effect caused by the ring itself. Genes for behavior disorders and scoliosis were assigned within the terminal 14q32.1q32.3 region, based on the presence of these clinical manifestations in subjects hemizygous for this region, because of either linear or ring deletion.

The patient carrying an apparently balanced t(10;14)(q25.3;q12) translocation had mental delay, retinitis pigmentosa, microcephaly, and seizures, in addition to a facial appearance similar to that seen in patients with a 14q proximal deletion (Fig. 3). No loss of genetic material was detected either by FISH or by high-resolution array-CGH in correspondence with either of the breakpoints.

Genotype-phenotype correlations, and relevant genes localized within the deleted intervals are summarized in Table II and in Figure 5.

### DISCUSSION

The delineation of the r14 syndrome, based on the present findings, is generally in good agreement with that of van Karnebeek et al. [2002], with few minor discrepancies. The prenatal history is usually normal, with term pregnancy and normal delivery. Intra-uterine growth retardation was observed only rarely among our patients and measurements at birth were usually normal, including a normal head circumference. On the other hand, postnatal growth delay and microcephaly tended to be the norm. A recurrent pattern of minor facial anomalies was observed, although it was limited to patients with deletions within the ring. The eye involvement consisted more often of mid-peripheral retinal pigmentation abnormalities. Surprisingly, major malformations were practically absent. Mental delay was found in all subjects, except for a girl with low-normal intelligence. She was carrier of a ring with no apparent loss of chromosomal material, and, more importantly, she had a less severe epilepsy, that resolved spontaneously at the age of 6 years. These children are usually good natured, but hyperactive, and with occasional bursts of aggressiveness.

The phenotype of those subjects (total six) who were carriers of a linear deletion of chromosome 14qter, differed substantially from that of the r14 syndrome, being generally less severe and



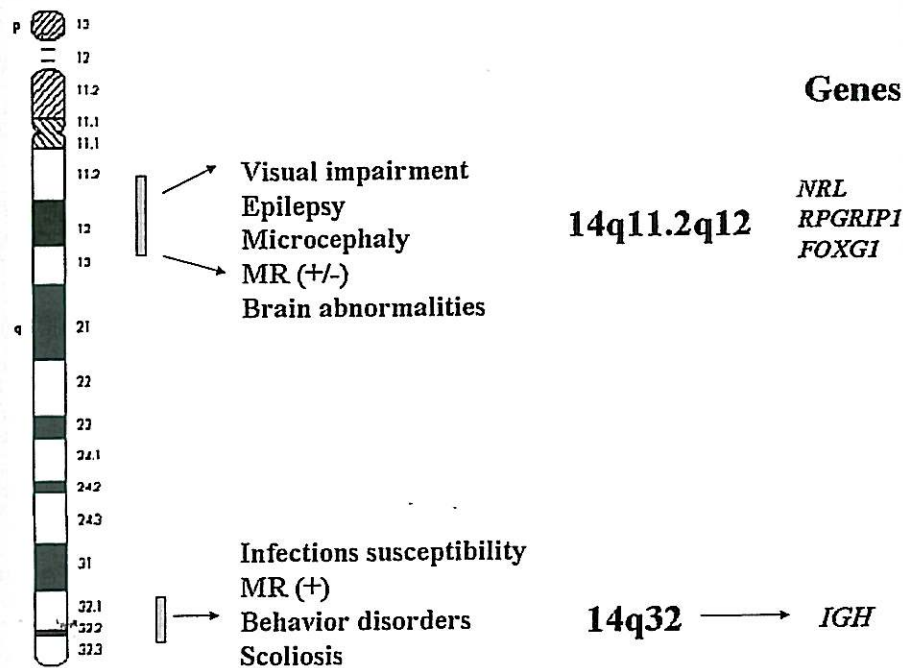


FIG. 5. Phenotypic map and relevant candidate genes for the distinctive clinical signs in both r14 and linear deletions.

without either epilepsy or retinal anomalies, although the loss of chromosomal material was larger, measuring 4.5 Mb in two patients, and 8, 11, 15, and 20 Mb in the other four patients, respectively. These patients also frequently presented with behavior disorders and scoliosis. On the other hand, acquired microcephaly, epilepsy, and visual impairment occurred in patients (total three) with a linear deletion affecting the proximal portion of chromosome 14q. As shown in Table III and in Figure 5, epilepsy, retinal anomalies, and acquired microcephaly were tentatively mapped to a 14q proximal region, while behavior disorders and scoliosis were mapped to a 14q distal region, varying in size from 4.5 to 20 Mb. Actually, one patient (patient 5) with a linear deletion affecting the 14q31q32 region had seizures (Table II). Interestingly, among a total of 15 patients reported by van Karnebeek et al. [2002] with linear deletions at or distal to 14q24, seizures were uncommon, with the only exception of one individual with a breakpoint at 14q32.11,

as in our patient. One can tentatively infer that a gene for seizures resides in this region as well.

As to the molecular characterization of the ring, 14 cases showed loss of 14q material starting from the telomere and extending for 0.65 Mb in three cases, 1.5 Mb in one case, 2.3 Mb in six, and 3.4, 3.8, 4.3, and 5.0 Mb in one of each remaining cases, respectively. The ring appeared to be complete in six cases, given that the 14q telomere was preserved, and the 75 kb resolution array-CGH gave normal results. However, in considering the breakage mechanisms leading to rings, a small 14q deletion had to be inferred, affecting a region of <70 kb at the very end of chromosome 14q. It is worth noting that, in Patient 11, a 2.5 Mb duplication was associated with a 3.4 Mb deletion. The clinical manifestations of this patient did not differ substantially from those of the other patients. Dup/del rearrangements were recently reported at a relatively high frequency in rings originating from different chromosomes, and were considered to be a relevant genetic factor in generating phenotypic variability [Rossi et al., 2008].

Lack of severe growth delay, the occurrence of acquired microcephaly in both linear deletions and ring chromosomes, and the presence of severe mental retardation, make the non-specific "ring syndrome" diagnosis unlikely in these cases [Cote et al., 1981; Kosztolányi, 1987]. Thus, we consider it more likely that clinical manifestations in the r14 syndrome are related to specific genes in chromosome 14 that undergo either true deletion or inactivation.

Having established a deletion map, as well as genotype-phenotype correlations, some further considerations are in order. The first thing to point out is that the two most distinctive manifestations of the r14 syndrome, namely epilepsy and retinal

TABLE III. Comparative Map of Clinical Signs Associated With Ring 14 and Linear Deletions, Either Proximal and Distal

	Ring 14	Linear 14q deletions	
		Proximal	Distal
Seizures	++	+	
MR	++	+	+
Visual impairment	+	+	
Behavior disorders	+		+
Scoliosis	+		+
Acquired microcephaly	+	+	

degeneration, are unlikely to be due to the 14q32q ter deletion, given that they are not found in subjects with a comparable linear deletion. We suggest that these traits may be assigned to the 14q11q13 region, containing the retinitis pigmentosa gene *RPGRIP1*, as well as the neural retina leucine zipper gene *NRL* [Farjo et al., 1997]. Also contained in the region is the *FOXG1B* gene, expressed in the developing fetal brain [Wiese et al., 1995]. Heterozygote KO mice show significant brain anomalies that might be the cause of epilepsy [Hanashima et al., 2002]. To support the involvement of this chromosomal region one would have to postulate the action of regulatory mechanisms, such as position effect. The formation of the ring could induce the spreading of heterochromatinization from the short arm of the chromosome down some distance to the long arm. Mitotic instability of the ring, as detected in all our patients, is likely to act as co-factor in the pathogenesis of this condition.

The phenotype of the r14 syndrome does not seem to be influenced by a parent-of-origin effect, given that microsatellite analysis demonstrated both paternal and maternal inheritance, perhaps with some prevalence of the paternal origin. All the rings appeared to have formed de novo, with the possible exception of one case, where the father was found to be a low mosaic for a ring 14 chromosome in peripheral blood. A possible effect of UPD 14 was also excluded, given that biparental inheritance of the ring and of the normal chromosome 14 was demonstrated in all cases analyzed.

The patient carrying the apparently balanced t(10;14)-(q25.3;q12) translocation deserves a final consideration. She had mental retardation, retinitis pigmentosa, microcephaly and seizures, in addition to a facial appearance, consistent with the 14q proximal deletion phenotype. Since no loss of genetic material was detected in either breakpoint regions, one could advance the hypothesis that the breakpoint on 14q12 inactivate pathogenic gene(s) by disruption or by silencing effect.

#### ACKNOWLEDGMENTS

We gratefully acknowledge the financial support of the Associazione Ring14, Reggio Emilia, Italy. We are also grateful to patients and families participating in this study.

#### REFERENCES

- Bisgaard AM, Kirchoff M, Tumer Z, Jepsen B, Brondum-Nielsen K, Cohen M, Hamborg-Petersen B, Bryndorf T, Tommerup N, Skovby F. 2006. Additional chromosomal abnormalities in patients with a previously detected abnormal karyotype, mental retardation, and dysmorphic features. *Am J Med Genet Part A* 140A:2180–2187.
- Cote GB, Katsantoni A, Deligeorgis D. 1981. The cytogenetic and clinical implication of a ring chromosome 2. *Ann Genet* 24:231–235.
- Farjo Q, Jackson A, Pieke-Dahl S, Scott K, Kimberling WJ, Sieving PA, Richards JE, Swaroop A. 1997. Human bZIP transcription factor gene *NRL*: Structure, genomic sequence, and fine linkage mapping at 14q11.2 and negative mutation analysis in patients with retinal degeneration. *Genomics* 45:395–401.
- Hanashima C, Shen L, Li SC, Lai E. 2002. Brain factor-1 controls the proliferation and differentiation of neocortical progenitor cells through independent mechanisms. *J Neurosci* 22:6526–6536.
- Kosztolányi G. 1987. Does “ring syndrome” exist? An analysis of 207 case reports on patients with a ring chromosome. *Hum Genet* 75:174–179.
- Menten B, Maas N, Thienpont B, Buysse K, Vandessompele J, Melotte C, de Ravel T, Van Vooren S, Balikova I, Backx L, Janssens S, De Paepe A, De Moor B, Moreau Y, Marynen P, Fryns JP, Mortier G, Devriendt K, Speleman F, Vermeesch JR. 2006. Emerging patterns of cryptic chromosomal imbalance in patients with idiopathic mental retardation and multiple congenital anomalies: A new series of 140 patients and review of published reports. *J Med Genet* 43:625–633.
- Rossi E, Riegel M, Messa J, Gimelli S, Maraschio P, Ciccone R, Stroppi M, Riva P, Perrotta CS, Mattina T, Memo L, Baumer A, Kucinkas V, Castellan C, Schinzel A, Zuffardi O. 2008. Duplications in addition to terminal deletions are present in a proportion of ring chromosomes: Clues to the mechanisms of formation. *J Med Genet* 45:147–154.
- Schlade-Bartusiak K, Costa T, Summers AM, Nowaczyk MJM, Cox DW. 2005. FISH-mapping of telomeric 14q32 deletions: Search for the cause of seizures. *Am J Med Genet Part A* 138A:218–224.
- van Karnebeek CDM, Quik S, Sluijter S, Hulsbeek MMF, Hoovers JMN, Hennekam RCM. 2002. Further delineation of the chromosome 14q terminal deletion syndrome. *Am J Med Genet* 110:65–72.
- Wiese S, Murphy DB, Schlung A, Burfeind P, Schmundt D, Schnulle V, Mattei MG, Thies U. 1995. The genes for human brain factor 1 and 2, members of the fork head gene family, are clustered on chromosome 14q. *Biochim Biophys Acta* 1262:105–112.